Re-Modeling Noses Without Leaving a Scar

How Modern Surgeons Build Up Nasal Cavities as Well as Remove Unsightly Humps and Thus Correct Nature's Bad Work

THE fashion of having the face and nose shaped by surgery to conform to certain ideals of beauty and attractiveness has taken a considerable hold on the women of New York.

The perfection of Cleopatra's nose is said to have decided the fate of the ancient world and our American women are eager for world power to-day.

The wisdom of having the nose altered simply for beautifying purposes may be seriously questioned, but it is apparent that many women are undergoing a complicated and expensive operation just for the sake of gaining a dignified straight nose line, a desirable curve or tilt, according to circumstances and tastes.

The surgical method of removing an unsightly hump from the bridge of the nose has recently been described in these pages. An operation, quite as much in favor and considerably more complicated is to fill up an unsightly depression in the bridge with bone taken from some other place.

Everybody knows that a nose badly pushed in and depressed at the bridge is a highly unattractive feature. There are a dozen or more different types of defective bridge, varying from absolute flatness to a small depression that merely gives you a commonplace look. If the depression is such as to interfere with nose breathing, any nose and throat surgeon will endeavor to open up the passage, but when it is a question of improving external looks, then a specialist of a more limited type is needed. A New York surgeon who has been very successful in performing such operations described that of bridge building to the writer.

The patient is put through the usual surgical steps with regard to cleanliness and asepsis. The face and area to be operated on are thoroughly cleaned with antiseptics. The hair and body are covered with cloths to prevent infection.

On the surgeon's table lie heaps of saws, chisels, scalpels, seizure forceps, hammers, tweezers, knives, rasps, scissors and other implements.

The operation is performed with local anesthesia alone. Cocaine is used to produce insensibility, and adrenalin to check bleeding.

In the first place an incision is made in the mucous membrane (lining) of the nose with a delicate knife. All the steps of the operation are performed within the nose without destroying any of the mucous membrane, which is cut through, and without injuring the exterior of the nose in any way.

Through the incisions in the mucous membrane a chisel is passed and the nasal bones are completely detached from the nasal process of the frontal bone (the forehead) and from the corresponding part of the upper jawbone. The nasal bones are then elevated sufficiently to raise the bridge of the nose to the desired ideal angle.

A small strip of antiseptic gauze is inserted underneath the detached nasal bones and holds them in the desired position. The tissue covering the nose is detached from the forward edge of the septum (partition) of the nose. The mucous surface lining the left side of the septum is lifted up and the patient is then ready for the insertion of the new bone, which will keep her nose permanently lifted up to the desired height.

A piece of bone, including its periosteal covering, is removed from the nose of another patient. This bone is usually taken from the vomer or bony structure of the septum or partition of the nose. The vomer is frequently cut away to enlarge the passage through the nostrils, and pieces of it can easily be spared.

The surgeon picks up the delicate bony morsel with a pair of tiny forceps, inserts it into the space between the detached mucous membrane and the nasal septum (partition) and places it in position so that the forward edge of this piece of new bone projects sufficiently to form the proper base of the new nasal bone.

Thus the original nose bridge is raised to its proper height by a bony prop under its foundation.

"Within two weeks the transplanted bone usually grows into place," said the surgeon who performed this operation. "I have found no changes in an operated nose after years."

A common condition that interferes with beauty is a one-sided nose. This condition may exist at the same time as one of the other defects and be cured by an operation at the same time as the other, or it may be the principal defect to be remedied in the patient.

To cure the one-sided condition, the surgeon takes his chisel and his saw and dislocates part of the bony structure of the nose from its foundation. The next step is to separate the upper part of the bony partition of the bone from its tissues. This is said to be very essential, as otherwise pushing the nose sideways might crack the "cribriform plate of the ethmoid cartilage," part of the base of the skull, which cracking might have disastrous consequences.

When he has loosened up everything so that it can be moved with safety, the beauty surgeon, with practised eye, pushes the nose towards the central line until it occupies the ideal position of straightness.

After the nose has been moulded into the desired shape, a strip of gauze is inserted through the first incision and is kept there for one or two days in order to establish drainage in case any infection should arise, otherwise the skin might tear on account of lack of downward drainage.

The nose is held in its newly fixed position by means of nasal splints until the parts have healed. This usually takes two or three weeks. At this stage the nose may still show a moderate degree of swelling, which, however, will gradually subside and within a few weeks more will have disappeared entirely.

Sometimes the apparent flatness of the bridge of the nose is really due to the unnatural pushing forward of the tip. Lower the tip and you may discover a perfect Grecian nose.

This condition is cured by a single operation by one New York surgeon. He introduces his angular scissors into the nostril and cuts out a triangular piece of the nasal partition, broad at the bottom and coming to a point at the top. The tip of the nose then drops down into a normalposition. The surgeon sews up the wound in the nose and healing under ordinary conditions takes place with great rapidity.

Cavities in the bones have been successfully filled with a paste of plaster containing a five per cent carbolic acid solution. Sunken noses have been raised with metal wire, metal plates, amber and hard rubber.

In many cases an entire nose lost by accident or disease has to be replaced by the surgeon. A very remarkable method of doing this with a piece of flesh from the upper part of the patient's arm is shown in an illustration on this page, taken from "Cosmetic and Plastic Surgery," by Dr. F. S. Kolle, fellow of the New York Academy of Medicine, published by D. Appleton & Co.

Remarkable results have been achieved by Professor Gersuny's method of injecting paraffin under the skin for the restoration of sunken noses and facial contours. One surgical authority states that it is rapidly taking the place of extensive transplantory and metal and bone plate operations for building up depressed noses and other abnormal cavities.

Paraffin is a fine wax made from coal tar, which liquefies at a temperature not too high to be borne, can then be injected under the skin and moulded into shape as it solidifies. Unlike most foreign substances, it is held by the tissues with perfect tolerance for an indefinite time.

The paraffin treatment is very useful in building up a flat or broken nose bridge. The surgeon lifts up the skin over the area with the fingers of his left hand as a guide to its mobility and to steady the part.

He pushes the point of a Pravaz syringe, filled with paraffin, under the skin at a point near the outer edge of the depression and pushes it a little beyond the centre of the cavity to be filled.

The elevation of the skin is partly kept up by the needle itself. The surgeon grasps the syringe with his free hand, the thumb and forefinger being placed upon the handle of the piston rod, which he relates in order to force the semi-solid mass from the instrument.

A nurse or assistant is instructed to press the skin around the depression in order to prevent the paraffin from filling up undesirable channels. It is most important that an excessive amount should not be injected, as it cannot be removed satisfactorily.

Before withdrawing the syringe the surgeon holds it in place for a time so that the semi-solid mass may not fill up the hole in the skin or leak out.

When the syringe is withdrawn the paraffin appears under the skin as a round or irregular lump, which must be worked into shape. The surgeon places the tip of one finger over the hole in the skin and then with the fingers of the right hand moulds the mass into the shape desired. More paraffin can be injected if needed in two or three days. The mass requires about three weeks to become thoroughly adapted to the tissues.

This treatment is said to be particularly effective for curing depressed nose bridges. In such cases the injection is made at one side in order to avoid making the puncture conspicuous. If the skin is very stiff it is prepared for the operation by massaging it for a few days in advance.

In order to mould the injected mass into the shape of a perfect, beautiful nose, the operator must be not only a skilfull surgeon but a good deal of an artist. It is most important in such cases that the surgeon should not inject even the least trifle too much paraffin for that will produce an ugly broadening of the nose. There is a thickening of the tissues after the operation, in addition to the increase in size due to the paraffin.

With the object of securing the finest esthetic result, the surgeon procures a nasal splint of aluminum covered on the inside with a fold of white gauze and pressed into such shape that when applied to the nose it will keep the latter pinched up to the desired width. This splint is not borne by the patient with comfort until after the slight inflammation that follows the operation has subsided. It is then held in place by strips of adhesive plaster for an hour or two in the day and during the entire night.

After the first few days' wearing the patient becomes quite used to the nose splint. It is worn in this way for about three weeks. Then it may be discarded and the surgeon will pinch his patient's nose two or three times a week to insure the best results.

By this simple and harmless method a perfectly ridiculous nose has been transformed into a delightful feature of faultless and fascinating beauty.

"The advantages of the Gersuny method," says a distinguished New York surgeon, "is that the operation is practically painless, causes no scar if properly performed and corrects a deformity that could not be overcome otherwise in some cases, while in others it would entail not only difficult surgical interferences, but subsequent unsightly scars that would render the remedy more objectionable than the very defects which were intended to be corrected."

The paraffin may also be used in the correction of depressions about the forehead resulting from violence or frontal sinus operations. It has even more surprising and esthetic uses. With a delicate hand, guided by long study of human faces, the surgeon can employ the paraffin to obliterate the furrows of habit between the eyebrows and the fixed frowns, and thus restore a prematurely aged face to a youthful and carefree appearance.

This wonderful paraffin will, it is said, fill out cheeks hollowed by sickness, grief or poverty and bring back an air of happiness and prosperity to faces that seemed doomed to lifelong sadness.

Even ugly droops about the chin that come with old age can be obliterated by this substance. Sunken furrows beneath the eyes can be smoothed away. Hollows about a woman's neck and shoulders can be filled out. The graceful and alluring outlines of the bust may be restored again after they have sagged down in an apparently hopeless manner.

In fact, some excellent authorities go so far as to say that any contour about any part of the body can be restored by paraffin.

The strangest part of this treatment is still to be described. In many cases it appears there is a growth of new connective body tissue in the part where the paraffin was injected, and the paraffin itself is absorbed by the tissues. Thus the lifeless foreign material which was injected to fill up a gap calls new living tissue into existence.

"This absorption following such an injection," says Dr. Kolle, "is productive of no harm to the human economy, and the new tissue caused to be formed by such injection truly enhances the cosmetic and surgical value of the method, inasmuch as a mass of paraffin as it exists after the operation is liable to displacement, spreading and irregularities, should it be subjected at any time to external violence.

"Such violence, again, would lead to the irritation and inflammation of the wall, causing an undue crowding upon the parts injected and possible gangrene of that part upon which pressure was brought to bear, leading to unsightly attachment and ultimate contraction of the skin where it is bound down by the inflammation.

"That the development of this connective tissue is gradual has been mentioned, some authors claiming a complete replacement of the mass at the end of a month, others from two or three months. Morton says that four months' time is required before the mass is, more or less, completely removed and replaced by organized tissue. The author believes, however, that the length of time necessary for this replacement not only varies but markedly with some patients in which the growth or developments of the new tissue did not cease for months and even a year after such injection.

"Time alone will show the ultimate behavior of this new tissue, and while it is reasonable to argue that this newly organized tissue could cause no untoward results, it must be determined whether this tissue will not undergo atrophy and contract, or become susceptible to other changes in time. It is a new tissue practically, and as yet we know nothing of its idiosyncrasies."

The development of modern nasal surgery has been specialized on in the clinic of St. Mark's Hospital, Eleventh street and Second avenue, New York City, where some of the operations described in this and previous nasal surgery articles were performed. The photographs shown in this article are those of patients operated upon at St. Mark's Hospital free clinic.

Photographs Before and After, Showing the Unsightly Nose of a Young Woman Which Was Built Up by a Surgeon Who Worked Through the Inside of the Nostrils and Thus Left No Scar to Secure the Face of the Patient.

The Two Types of Noses Which Require Quite Different Attention—Those Where Something Must Be Cut Away and Those Which Require Building Up.

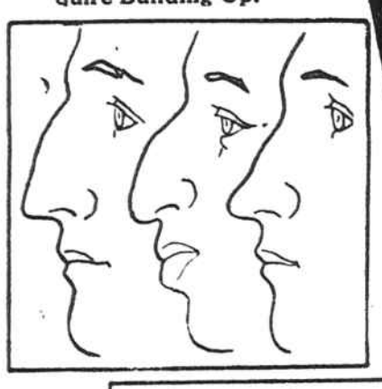

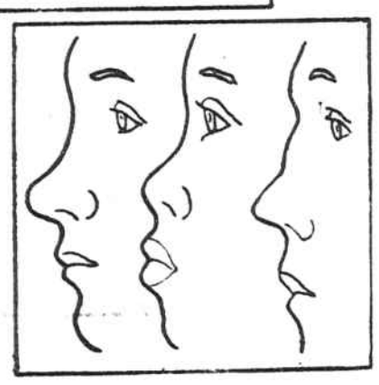

The Unattractive Face of a Patient at the Free Clinic and the Rather Attractive Face After the Nose Was Remodeled.



Before and After Photographs of a Young Man Whose Nose Was Operated On to the Considerable Improvement of His Appearance.

How Modern Surgery Builds an Entirely New Nose When Necessary.

This Diagram, from "Plastic and Cosmetic Surgery," by Dr. F. S. Kolle, Published by D. Appleton & Co., Shows How an Incision Is Made in the Patient's Arm and the Flesh Is Grafted to the Face for the Purpose of Growing a New Nose. The Arm Must Be Kept Rigidly in Position for Several Days by the Appliance Shown Above.

Copyright, 1919, by Star Company.

Great Britain Rights Reserved.